

Disseminated Burkitt's Lymphoma with a Pancreatic Mass in a HIV Positive Woman Diagnosed by Axillary Lymph Node Biopsy

GODFREY MUTASHAMBARA RWEGERERA¹, YORDANKA PINA RIVERA², FENG ZHOU³, KUDRA JUMANNE CHOBANGA⁴, SHEIKH OMAR SESAY⁵

ABSTRACT

Burkitt's Lymphoma (BL) is a highly aggressive B cell lymphoma of non Hodgkin's type usually presenting in extranodal sites for endemic and sporadic types of the disease. Like other Non-Hodgkin's Lymphomas (NHL), HIV positive associated BL is associated with peripheral Lymphadenopathy. We present a case of 22-year-old newly diagnosed HIV positive female patient who presented with generalized peripheral lymphadenopathy and obstructive jaundice. Initial work up was suggestive of acute pancreatitis with further evaluation revealing a pancreatic head mass. BL was confirmed both by axillary lymph node biopsy and immunohistochemistry highlighting the importance of high index of suspicion and prompt histopathological diagnosis to enable treatment of this fatal disease that is potentially curable.

Keywords: Ebstein-barr virus, Fatal outcome, Immunodeficiency, Neoplasms, Young adult

CASE REPORT

A 22-year-old female, newly diagnosed HIV positive who was not yet placed on antiretroviral medications was referred to Princess Marina Hospital, a tertiary center in Gaborone, the capital city of Botswana. She had presented at a local hospital with history of right upper quadrant abdominal pain of one month duration which worsened with time, also she was noted to have sclera jaundice. The abdominal pain was more at the hypogastic region with radiation to the back. She admitted to have a history of fevers associated with occasional chills, nausea, non-projectile vomiting post feeds and loss of appetite with loss of 8 kilograms weight in the span of six weeks. Initial assessment at the referral hospital revealed a chronically ill looking lady, cachectic, pale with deep sclera icterus, she had generalized peripheral lymphadenopathy involving cervical, axillary and inguinal regions; most of the lymph nodes palpable were rubbery in consistency. She was febrile at 38.3° C with pulse rate of 122 beats per minute, Blood pressure of 99/50mmHg and respiratory rate of 18 breaths per minute and 100% saturation on room air. Systemic examination was significant for abdominal findings with tender hepatomegaly of 6 cm below right costal margin and liver span of 14 cm. Other systems including nervous, cardiovascular and respiratory were unremarkable. Patient baseline blood results were as shown in [Table/Fig-1]; they revealed leukocytosis, normocytic anaemia and liver enzymes showed obstructive picture and excisional biopsy sample was obtained from the left axillary gland and sent to National Health laboratory for diagnosis. Abdominal pelvic ultrasound revealed hepatomegaly of 16.5 cm, with hypoechoic nodules noted in the right middle lobe, measuring 52.1 x 47.7 x 17.4 mm. The pancreas was diffusely enlarged with hypoechoic texture; enlarged lymphnodes in the porta-hepatis, paraaortic and inguinal regions were also observed, with the largest lymphnode at right inguinal region measuring 61.6 x 45.6 mm. Initial chest radiography was normal without any evidence of cardiomegaly, hilar adenopathy or pleural effusion. Computed Tomography (CT) scan of the abdomen performed on day 4 post-admission revealed moderate ascites, hepatomegaly with enlarged intrahepatic ducts. The pancreas was diffusely enlarged with pancreatic head mass measuring 7.74 x 5.61 cm [Table/Fig-2] and mixed densities of 14.3 HU to 60 HU post contrast with moderate

Laboratory investigation	Patient results	Reference value
WBC	16.95	4-11
Hb	6.4 g/dl	12-15
MCV	81.2 fl	83-99
PLT	646 x 10 ³ /μL	150-400 x 10 ³
Serum creatinine	56 μmol / l	50-99
Urea	4.2 μmol / l	2.9-7.1
Serum Na+	133 μmol / l	135-145
Serum K+	5.0 μmol / l	3.5-5.1
Alkaline phosphatase (ALP)	>1853 U/l	35-129
Gamma-Glutamyltranspeptidase (GGT)	1239 U/l	11-50
Alanine aminotransferase (ALT)	280 U/l	11-41
Aspartate aminotransferase (AST)	446 U/l	10-34
Total bilirubin	169 μmol/l	1-25.7
Conjugated bilirubin	153 μmol/l	0-3
Lactate dehydrogenase (LDH)	2055 U/l	60-160
Hepatitis B surface antigen	Negative	
Hepatitis C antibodies	Negative	
Urine for culture and sensitivity	No growth in after hours	
Blood for culture and sensitivity	No growth after seven days	
Beta HCG	Negative	
Alpha feto protein	2.4 ng/dl	0-20

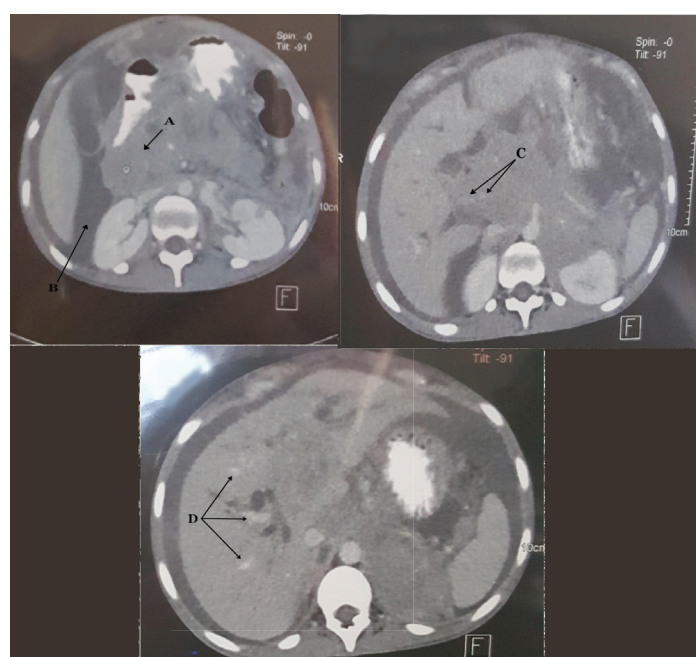
[Table/Fig-1]: Laboratory investigations of the patient.

ascites [Table/Fig-2]. The common bile duct was grossly enlarged. Both kidneys were normal in shape, position and size. Generalized lymphadenopathy involving peri-pancreatic, porta-hepatis, para-aortic [Table/Fig-2] and para-caval regions were also observed. There were multiple hepatic masses and periportal nodes [Table/Fig-2] and the spleen appeared normal. CT chest was significant for bilateral pleural effusion without mediastinal or hilar adenopathy. Histology results of the left axillary nodes were as follows; Gross findings of the excisional biopsy from the axillary lymph node revealed two ovoid grey brown encapsulated masses; one 3.5 x 3 x 2.4 cm and the other 3.8 x 3 x 1.8 cm. All cut-sections appeared yellow and soft with foci of haemorrhage and necrosis. Microscopy

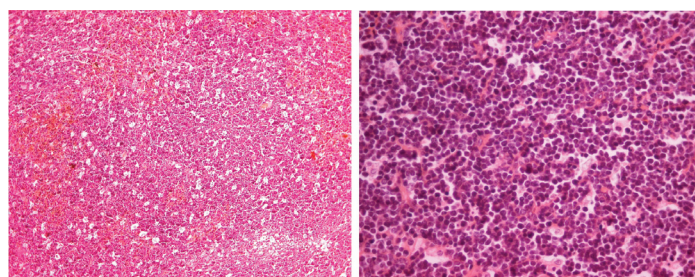
revealed a starry-sky pattern impacted by interspersed tangle-body macrophages [Table/Fig-3]; there was diffuse infiltrate of medium-sized malignant lymphoid cells with round nuclei, coarse chromatin, two to three basophilic nucleoli and scanty cytoplasm [Table/Fig-4]. Frequent mitoses, foci apoptotic bodies and haemorrhage were also seen. The histological features were consistent with a high grade NHL, favoring BL. Immunohistochemistry of the tumor cells showed diffuse nuclear PAX-5 positivity, CD10 and CD20 positivity, 100% KI 67 expression and Epstein-Barr Virus (EBV) in-situ hybridization was also positive [Table/Fig-5] whereas BCL6, BCL2, CD3 and MUM1 were negative [Table/Fig-6]. The conclusion was of high grade NHL of burkitt's type and oncology review was sought urgently. Over the course of admission patient received supportive care that included analgesia, dietary support, intravenous fluids and three packs of blood transfusion Patient condition worsened over the course of admission with new onset worsening shortness of breath saturating at 80-88% on oxygen therapy; this was despite therapeutic thoracocentesis. Oncology assessment for chemotherapy was of critically sick patient who was not fit for chemotherapy, patient died on day 12 of admission and next of kin did not consent to autopsy.

DISCUSSION

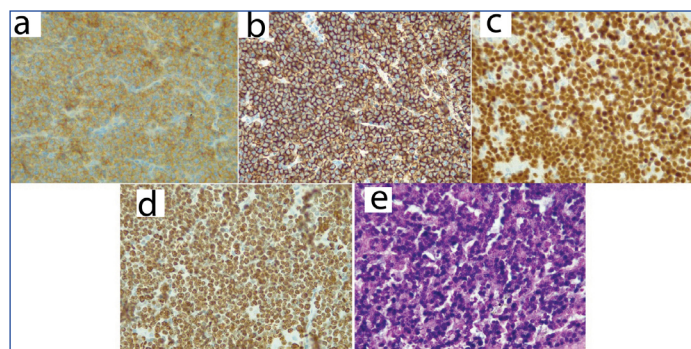
BL is a highly aggressive B type of NHL in human beings with highest proliferation rate and potential to double number of tumor cells within 24 hours [1]. It has three main varieties; endemic BL, sporadic BL and immunodeficiency-associated BL [2,3]. Acquired Immunodeficiency Syndrome (AIDS), congenital immunodeficiency syndromes and patients with allograft transplants comprises the immunodeficiency category [4]. The pathogenetic hallmark of BL



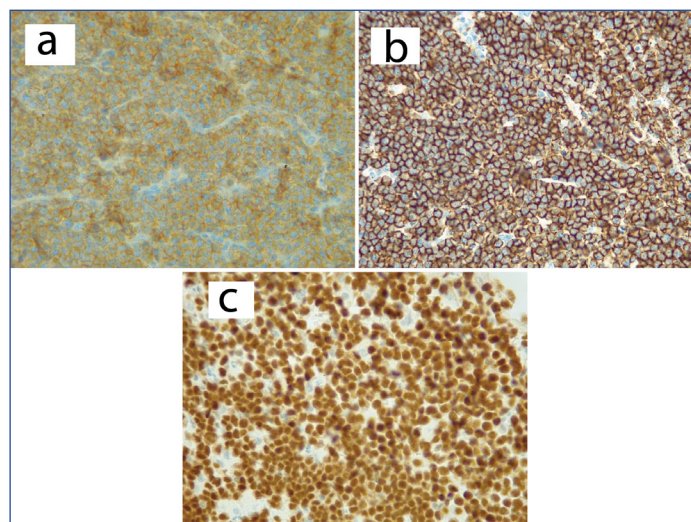
[Table/Fig-2]: Findings are consistent with diffuse enlarged pancreas with pancreatic head mass (a) and ascites (b); peri-pancreatic lymph nodes (c) and multiple hepatic masses and porta-hepatic nodes (d).



[Table/Fig-3]: (3) Biopsy showing a monotonous lymphoid diffuse infiltrate with a starry-sky appearance (10x10; H and E stain). **[Table/Fig-4]:** Biopsy showing medium sized neoplastic cells with round nuclei, coarse chromatin, multiple distinct nucleoli and frequent mitoses (10 x 40; H and E stain).



[Table/Fig-5]: Positive immunohistochemistry stains for CD10 (a), CD20 (b), PAX-5 (c), KI 67 expression (d) and EBV positive in-situ hybridization (e).



[Table/Fig-6]: Negative immunohistochemistry stains for BCL-2 (a); BCL-6 (b); and MUM1 (c).

is rearrangement of the c-myc oncogene which is an important regulator of cell proliferation and apoptosis [5]. The typical reciprocal chromosomal translocations in BL include: t (8; 14) (q24; q32) or their rare variants: t (8; 22) (q24; q11) or t (2; 8) (q12; q24) [6,7]. The pathogenesis of HIV-associated BL is linked to oncogenic virus co-infection with about 40% association with EBV. EBV cause chronic HIV antigen stimulation that provokes expansion of polyclonal B-cells [8]. The patient presented in this case report was positive for EBV as it revealed by EBV in-situ hybridization.

Our patient presented with advanced disease with generalized peripheral lymphadenopathy, multiple hepatic masses and involvement of multiple lymph node regions in the abdomen. Involvement of pancreas either as diffuse or with a pancreatic mass as it occurred in this case is rare [9,10]. Initial ultrasonography was consistent with acute pancreatitis; this is similar to previous reported cases [9, 11]. On the other hand, BL is typically associated with extranodal disease in immunocompetent individuals [12];-HIV associated BL has been documented to involve peripheral lymph nodes [13] as it occurred in this case providing room for less invasive diagnostic modality; furthermore mediastinal lymph nodes are always spared in BL [13], as it occurred in our patient.

Involvement of pancreas in lymphoma poses a challenge of distinguishing origin as to whether lymphoma is of pancreatic origin or diffuse infiltration from adjacent lymph nodes; - this is due to the fact that the pancreas lacks a capsule [14]. According to Behrns KE et al., who categorized lymphomas of pancreatic origin to have involvement of peripancreatic lymph nodes without splenic and hepatic metastasis, and absent of other enlarged distal elsewhere together with normal white blood cells; this classification clearly makes our patient pancreatic mass and diffuse involvement to be more of an infiltration rather than primary pancreatic origin as there was distal enlarged nodes, leukocytosis and hepatic involvement [15]. On the other hand, pancreatic involvement from adjacent lymph

node involvement in NHL has been reported in up to 30% of cases and in most cases resampling acute pancreatitis as it appeared in our patient [9,11].

Our patient presented with obstructive jaundice; this is a very rare observation in NHL [16] as it has been reported only in about 1% of cases at presentation [12]. Obstructive jaundice usually occurs at the level of distal common bile duct and liver hilum secondary to compressing lymph nodes [17].

Use of immunohistochemistry has been found to be useful in confirming diagnosis of BL in cases where histology findings are not definitive. Presence of positive CD20, CD10 and 100% KI 67 expression confirm the diagnosis of BL [2,18,19]. The presented patient had both characteristic histology findings of macrophages depicting a "starry-sky" appearance [3,18] and described immunohistochemistry findings.

CONCLUSION

BL is a highly aggressive NHL with high response to chemotherapy when prompt diagnosis is made. HIV- associated BL tends to involve peripheral nodes providing room for less aggressive diagnostic approaches. Despite the fact that obstructive jaundice is a rare finding in NHL including BL, its presence should always alert a possibility of disseminated lymph nodes associated with lymphoma.

ACKNOWLEDGEMENTS

We would like to thank Dr Julian Deonarain, Department of Histopathology from Lancet laboratories in Durban (Republic of South Africa) for retrieving and providing us with the histology photographs.

REFERENCES

- [1] Kemp S, Gallagher G, Kabani S, Noonan V, O'Hara C. Oral non- Hodgkin's lymphoma: review of the literature and World Health Organization classification with reference to 40 cases. *Oral Surg Oral Med Oral Pathol Oral Radiol Endod.* 2008;105:194-201.
- [2] Sangma MM, Dasiah SD, Ashok AJ. Ileo-colic burkitt lymphoma in a young adult female-a case report. *Journal of Clinical and Diagnostic Research.* 2016;10(4): 11-12.

- [3] Patankar S, Venkatraman P, Sridharan G, Kane S. Burkitt's lymphoma of maxillary gingiva: A case report. *World J Clin Cases.* 2015;3(12):1011-16.
- [4] Biko DM, Anupindi SA, Hernandez A, Kersun L, Bellah R. Childhood Burkitt lymphoma: abdominal and pelvic imaging findings. *American Journal of Roentgenology.* 2009;192(5):1304-15.
- [5] Park YH, Kim WS, Kang HJ, Na II, Ryoo BY, Yang SH, et al. Gastric Burkitt lymphoma is a distinct subtype that has superior outcomes to other types of Burkitt lymphoma/leukemia. *Ann Hematol.* 2006;85:285-90.
- [6] Ugar DA, Bozkaya S, Karaca I, Tokman B, Pinarli FG. Childhood craniofacial Burkitt's lymphoma presenting as maxillary swelling: Report of a case and review of literature. *J Dent Child (Chic).* 2006;73:45-50.
- [7] Neville BW, Damm DD, Allen CM, Bouquet JE. Soft tissue tumors. In: Neville BW, Damm DD, Allen CM, Bouquet J, editors. *Oral and Maxillofacial pathology.* 3rd ed. St. Louis: W.B. Saunders Elsevier, 2009: 557-559.
- [8] Molyneux EM, Rochford R, Griffin B, Newton R, Jackson G, Menon G, et al. Burkitt's Lymphoma. *Lancet.* 2012;379:1234-44.
- [9] Mahajan V, Qian Y, Blake B, Rojas-Khalil Y, Radhakrishnan RS, Muthukumar A. Sporadic Burkitt lymphoma presenting as acute pancreatitis, concurrent sinusitis, and enlarged adenoids. *Case Reports in Pediatrics.* 2016;2016:3862175.
- [10] Sa lam M, Yilmaz MI, Mas MR, Ta çı I, Örs F, Sönmez A, et al. A case of pancreatic Burkitt lymphoma: radiological findings. *Diagn Interv Radiol.* 2009;15:39-42.
- [11] Bacchi LM, Ucella I, Amancio TT, Gonçalves MC, Palhares RB, Siqueira SAC. Burkitt lymphoma mimicking acute pancreatitis. *Autopsy Case Rep [Internet].* 2012; 2(3):5-11.
- [12] Odemis B, Parlak E, Basar O, Yuksel O, Sahin B. Biliary tract obstruction secondary to malignant lymphoma: experience at a referral center. *Digestive Diseases and Sciences.* 2007;52(9):2323-32.
- [13] Kanbar AH. Burkitt Lymphoma and Burkitt-like Lymphoma Clinical Presentation. <http://emedicine.medscape.com/article/1447602-clinical>. Last accessed on 15th April 2017.
- [14] Guermazi A, Brice AP, De Kerviler E, Fermé C, Hennequin C, Meignin V, et al. Extranodal Hodgkin disease: spectrum of disease. *Radiographics.* 2001;21(1): 161-79.
- [15] Behrns KE, Sarr MG, Strickler JG. Pancreatic lymphoma: is it a surgical disease? *Pancreas.* 1994;9(5):662-67.
- [16] Chaudhari D, Khan S, Saleem A, Taylor T, Reddy C, Borthwick T, et al., Obstructive jaundice as an initial manifestation of non-hodgkin lymphoma: treatment dilemma and high mortality. *Case Reports in Medicine.* 2013;2013:259642.
- [17] Ravindra KV, Stringer MD, Prasad KR, Kinsey SE, Lodge JP. Non-Hodkin Lymphoma presenting with obstructive jaundice. *Br J Surg.* 2003;90:845-49.
- [18] Kılınç A, Saruhan N, Tepecik T, Gündoğdu B. Burkitt's lymphoma presenting as maxillary swelling: case report. *Middle Black Sea Journal of Health Science.* 2016;2(2):29-32.
- [19] Mehanna KH, Telles JEQ, Mauro DP. Burkitt's lymphoma presenting as jejunojejunal intussusception in a child: A case report. *Int J Case Rep Images.* 2017;8(2):96-100.

PARTICULARS OF CONTRIBUTORS:

1. Senior Lecturer, Department of Internal Medicine, Faculty of Medicine, University of Botswana and Princess Marina Hospital, Gaborone, Botswana.
2. Lecturer, Department of Internal Medicine, Faculty of Medicine, University of Botswana and Princess Marina Hospital, Gaborone, Botswana.
3. Pathologist, Department of Histopathology, National Health Laboratory Gaborone, Botswana.
4. Lecturer, Department of Obstetrics and Gynecology, Faculty of Medicine, University of Botswana and Princess Marina Hospital, Gaborone, Botswana.
5. Consultant, Department of Radiology, Princess Marina Hospital, Gaborone, Botswana.

NAME, ADDRESS, E-MAIL ID OF THE CORRESPONDING AUTHOR:

Dr. Godfrey Mutashambara Rwegerera,
Private Bag 00713, 4775 Notwane Road. Gaborone, Botswana.
E-mail: grwege@yahoo.com

Date of Submission: **Feb 11, 2017**

Date of Peer Review: **Apr 07, 2017**

Date of Acceptance: **Jun 07, 2017**

Date of Publishing: **Aug 01, 2017**

FINANCIAL OR OTHER COMPETING INTERESTS: None.