



Contents lists available at ScienceDirect

Journal of Pediatric Surgery Case Reports

journal homepage: www.jpascasereports.com

Fetus-in-fetu in Botswana

Chowdhury Goutam^a, Francis Msume Banda^{b,*}^a University of Botswana, Department of Paediatric Surgery, Princess Marina Hospital, Gaborone, Botswana^b University of Botswana, Department of Paediatrics, Princess Marina Hospital, Gaborone, Botswana

ARTICLE INFO

Article history:

Received 20 June 2017

Received in revised form

12 July 2017

Accepted 14 July 2017

Available online 17 July 2017

Keywords:

Fetus-in-fetu

Teratoma

Botswana

ABSTRACT

Fetus-in-fetu is a medical term that describes a fetus implanted within its twin, on whom it is entirely dependent for its survival through a vascular connection. It occurs in about 1 in 500,000 live births. So far, there are just under 100 cases that have been reported in the medical literature.

We report about a first case of fetus-in-fetu in a full-term baby born in Botswana. We also review the medical literature regarding this diagnosis.

We conclude that all fetus-in-fetu cases should be managed with extreme caution as if they; were teratomas, in view of the latter's malignant potential. Early surgery of the host twin; should be the primary consideration. It would be prudent if gravid women with suspicious; abdominal findings on antenatal ultrasound were delivered in a referral centre, as this would; lead to better care and survival of the infant with fetus-in-fetu.

© 2017 The Authors. Published by Elsevier Inc. This is an open access article under the CC BY-NC-ND license (<http://creativecommons.org/licenses/by-nc-nd/4.0/>).

1. Introduction

Fetus-in-fetu is quite a bewildering condition. A fetus is implanted within its monozygotic monochorionic diamniotic twin [1,2] on whom it is completely reliant for its survival through a vascular connection [1,3,4].

Twin-to-twin transfusion is believed to play a major role in the pathogenesis of this condition [5]. It is a very rare condition, occurring in about 1 in 500,000 live births, with just under 100 cases described in case reports [1,6]. This is the first such case that we have reported from Botswana.

2. Case report

A full-term female baby was born by elective caesarean section at 38-weeks' gestation to a 38-year-old primigravid woman. The baby was born with birth weight 3200 g and Apgar scores 7/10, 8/10, and 9/10 at 1, 5, and 10 min postpartum respectively. There were no dysmorphic features. The indication for the caesarean section was a foetal mass detected during the mother's routine antenatal obstetric ultrasound scans. At 20/40 gestation, the mother's

obstetric ultrasound showed a single viable fetus with an estimated foetal weight of 1999g who had a septate, cystic mass in the right kidney measuring 3 cm × 3 cm × 2 cm. The left kidney appeared normal. The placenta was anterior and there was adequate amniotic fluid volume. Repeat obstetric ultrasound at 24/40 gestation showed similar findings with an interval increase in the size of the mass to 3 cm × 3.87 cm × 6.38 cm.

Despite the obstetric ultrasound findings, the mother had no problems in the antenatal period. She tested negative for HIV and syphilis in pregnancy. Her antenatal drug history only included folic acid and multivitamin tablets. Her serial blood sugar and blood pressure measurements were all within normal limits. She was married to an unrelated spouse and there was no family history of twin pregnancy or congenital malformations on either side. Caesarean section was uneventful. The baby had no respiratory distress and quickly adapted to breast feeding. She had a mildly distended abdomen with a soft mass in the right upper half of the abdomen, measuring about 8 cm long and 8 cm wide on palpation. The right kidney could not be palpated separately from the mass. The liver and spleen were not palpable and there were no signs of ascites. An abdominal ultrasound showed a complex cystic mass in the right upper quadrant of the abdomen measuring 9.5 cm × 7.1 cm × 6.4 cm and displacing the right kidney anteriorly. The lower pole of the right kidney could not be clearly visualized. On abdominal CT scan, the mass appeared to have mixed solid and calcified areas of heterogeneous densities enclosed in a multicystic structure with low level echoes, and was displacing the

* Corresponding author. University of Botswana, Faculty of Medicine, Department of Paediatrics, P/Bag 00713, Gaborone, Botswana.

E-mail addresses: goutam.chowdhury@mopipi.ub.bw (C. Goutam), fmbanda@yahoo.co.uk, Francis.Banda@mopipi.ub.bw (F.M. Banda).

right kidney. The mass appeared to be attached to the right kidney. The mass had clearly-visible vertebrae (Fig. 1). The CT diagnosis was teratoma. Renal and liver function tests (RFTs/LFTs) were all within normal limits. Laparotomy was deferred at the time due to the unavailability of a paediatric surgeon and also because the distension at the time was deemed to be mild.

At the age of 2 months, the baby was noted to have tense abdominal distention with moderate respiratory distress. There were no feeding problems and she was passing urine and stool well. Her weight and height were within normal limits for age and sex. She was afebrile. Oxygen saturation in room air was 95%, improving to 100% in oxygen by nasal prongs. There were moderate intercostal and subcostal recessions but no tracheal tagging, head nodding or central cyanosis. Lung fields were clear on auscultation. She was well-perfused with full volume pulses. Capillary refill time was less than 2 s. The abdomen was even more distended than before, with a palpable mass on the right half of the abdomen, measuring about 12 cm long and 10 cm wide, with a soft feeling.

It appeared to be separate from the liver above. There was no jaundice and the kidneys were not ballotable. There was no shifting dullness or fluid thrill (Fig. 1). The rest of the physical examination was unremarkable. Full Blood Count (FBC), Renal Function Tests (RFTs) and Liver Function Tests (LFTs) were all within normal limits. Serum Alpha fetoprotein was 1539.7 (normal range at age of 2 months: 45–601 ng/mL) [7]. Chest X-ray did not show any infiltrations.

Laparotomy was done at the age of two and a half months. A partially cystic and partially solid fetoid mass was noted in the subhepatic area, adherent to both the right kidney and the liver, and pushing down the right kidney. It was covered with a thin membrane and weighed 338 g after 200 mL of serous fluid were aspirated from the cyst during the surgery. It was excised totally

and was noted to have been fed directly by a vascular branch from the baby's abdominal aorta. Separation and excision of the mass was not difficult.

At this point we thought that the mass was probably a retro-peritoneal teratoma. After opening the cyst, we drained 750 ml of straw colour fluid and then noted that the fetoid mass had well-formed upper limbs and a well-delineated back (Fig. 1). There was no cardiac activity. No radiological examination of the specimen was done.

Histopathological examination of the excised mass showed that it had both mesodermal and ectodermal components with numerous skin and adnexal structures. Subcutaneous mature and immature adipose tissue was seen, together with smooth muscle, skeletal muscle, cartilaginous bone and neural tissue. Two well-formed adrenal glands were also present. The sac of the cyst was lined with multivariate epithelium, including intestinal, respiratory, striated squamous and simple cuboidal. There was no malignant transformation. These histopathological findings were consistent with a diagnosis of either a fetus-in-fetu or a highly-organized teratoma. Karyotyping and DNA studies were not done due to lack of resources.

The child has been growing well and attaining milestones timeously. She was seen again at the age of 4 months. Her anthropometry were as follows: weight 7 kg, length 65 cm, weight-for-age 0 to +1 Z-scores, weight-for-length 0 Z-score, length-for-age 0 Z-score and head circumference 42 cm (0 Z-score). She had no respiratory distress and her vital signs were all within normal limits. Her serum α -Fetoprotein had now normalized at 32 ng/mL (normal range at age of 4 months: 18–130 ng/mL) [7]. Full Blood Count (FBC), Renal Function Tests (RFTs) and Liver Function Tests (LFTs) were again within normal limits. A follow-up ultrasound scan of the abdomen was normal.

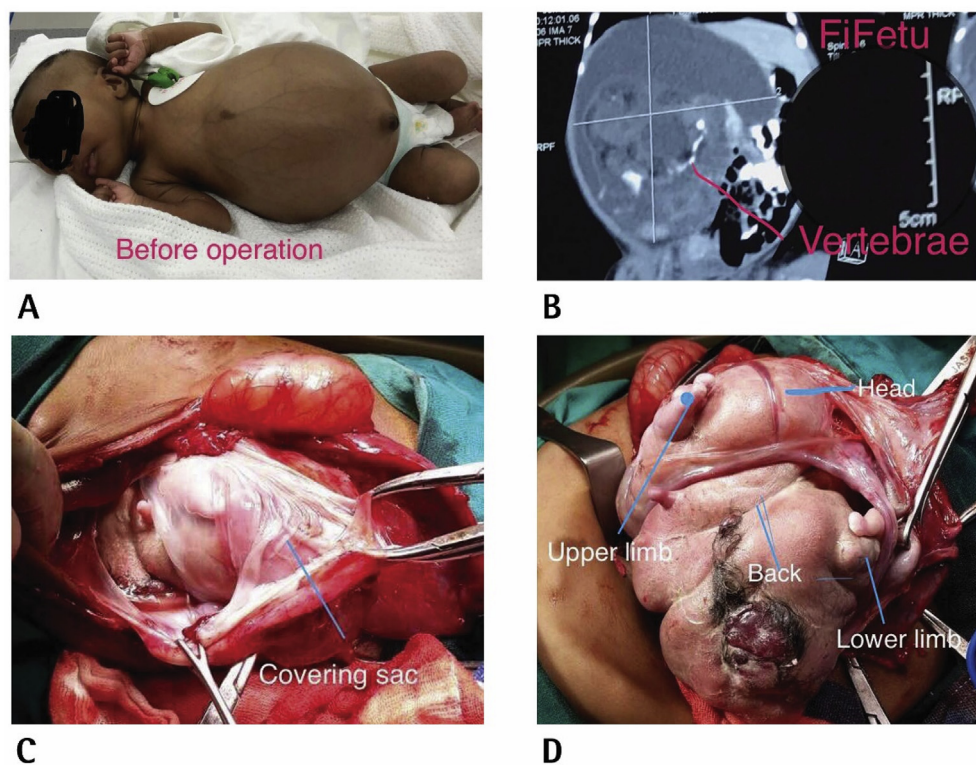


Fig. 1. A & B are preoperative images-note the huge abdominal distension with visibly distended veins and multiple abdominal contours due to the intra-abdominal mass (A). Also note the vertebral column of the foetal mass on CT abdomen (B). C&D are intraoperative images-note the fetoid mass, covered in a well-formed sac (C). The fetoid mass appears hairy, with a well-formed back and appendages (D).

The child's most recent review was at the age of 8 months. Her anthropometry were all plotting on the 0 Z-score and she was thriving well. Her serum α -Fetoprotein was 18.2 ng/mL (normal range at age of 8 months: 3–14 ng/mL) [7]. Full Blood Count (FBC), Renal Function Tests (RFTs) and Liver Function Tests (LFTs) were normal. A repeat ultrasound scan of the abdomen was normal. We plan to see the child again at the age of 2 years, with the intention to discharge her from follow-up at that time.

3. Discussion

Our fetus-in-fetu was a single entity, with a retroperitoneal location. This is consistent with what has been reported in the medical literature (88% single, and 88% retroperitoneal), with a maximum of 11 fetoid forms in a single fetus according to Gerber et al. [8] We initially thought of a retroperitoneal teratoma, but the presence of vertebrae, well-formed appendages and a skin-covered trunk on clinical inspection together with well-differentiated smooth muscle, skeletal muscle and two well-formed adrenal glands on pathological examination was more in keeping with fetus-in-fetu, which by consensus, should have an axial skeleton and complex, well-differentiated tissues [1,9]. These features are often lacking in a teratoma [10,11], although there is contrary opinion suggesting that fetus-in-fetu may represent a well-differentiated and highly organized teratoma [12]. The spontaneous post-surgical normalization of child's serum alpha-fetoprotein (AFP) was also more in keeping with fetus-in-fetu than with a well-differentiated teratoma. Fetus-in-fetu is generally an innocuous condition, and although the AFP was elevated before the surgery in our child, it is usually within normal limits both pre- and post-surgical excision of the fetus-in-fetu [13]. Of all the fetus-in-fetu cases that have been reported in the medical literature so far, only one was reported to have been malignant [14]. We therefore continued to do serial AFP measurements in our child post-surgery, while also bearing in mind that a well-differentiated teratoma has a more than 10% malignant potential [15].

Our child was generally "normal" except for the respiratory distress. This presentation was also in keeping with what has been reported in the medical literature, where the host twin is rarely found to have any associated anomalies, notwithstanding the mass effect from the lesion, like a distended abdomen and vomiting, among others [5,16]. The deferral of surgery for our child in this report may have contributed to the development of the respiratory distress, as the fetus-in-fetu kept growing during this waiting time. The impact of the waiting time on the child would have been worse had the fetus-in-fetu been malignant or had it turned out to be a teratoma, whose malignant potential has been pointed out above.

Our fetus-in-fetu was dependent on a branch from the aorta of the host twin. This has been reported before in several sources, some of which have specifically mentioned the superior and inferior mesenteric vessels as well as the left renal vein [15,17,18]. The ultimate distinction between a fetus-in-fetu and a teratoma is done by genotypic and methylation studies [2] which we were unable to do in our child due to resource limitations. In almost all cases, these studies show that the fetus-in-fetu and the host infant have a homology of chromosomes 14 and 15, a feature which has not been seen in teratomas [2,8].

In conclusion, we have reported about a fetus-in-fetu for the first time in Botswana. The distinction between fetus-in-fetu and a

well-organized teratoma may be extremely difficult in the absence of genotype and methylation analyses, but serial AFP monitoring pre- and post-surgery may be helpful, and should continue until it comes down to within normal limits. Lastly, all fetus-in-fetu cases should be managed with extreme caution as if they were teratomas, in view of the latter's malignant potential. Early surgery of the host twin, as far as resources permit, should therefore be the primary consideration. It would be prudent if gravid women with suspicious abdominal findings on antenatal ultrasound were delivered in a referral centre, as this would lead to better care and survival of the infant with fetus-in-fetu.

Conflict of interest

There are no conflicts of interest to declare.

Acknowledgements

The authors would like to sincerely thank the mother of the child for providing informed consent to publish all the content of this case report.

References

- [1] Brand A, Alves MC, Saraiva C, Loio P, Goulão J, Malta J, et al. Fetus-in-fetu: diagnostic criteria and differential diagnosis- a case report and literature review. *J Paediatr Surg* 2004;39:616–8.
- [2] Miura S, Miura K, Yamamoto T, Yamanaka M, Saito K, Hirabuki T, et al. Origin and mechanisms of formation of fetus-in-fetu: two cases with genotype and methylation analyses. *Am J Med Genet A* 2006 Aug 15;140(16):1737–43.
- [3] Tran MN, Landin MD, Blackwood BP, Shah AN. Fetus in fetu-a case report with a variant host anastomosis. *Am Surg* 2016 Sep;82(9):759–62.
- [4] Spencer R. Parasitic conjoined twins: external, internal (fetuses in fetu and teratomas), and detached (acardiacs). *Clin Anat* 2001 Nov;14(6):428–44. Review.
- [5] Kaufman D, Du L, Velcek FT, Alfonso AE. Fetus-in-Fetu. *J Am Coll Surg* 2007 Aug;205(2):378–9. Epub 2006 Oct 25.
- [6] Grant P, Pearn JH. Foetus-in-foetu. *Med J Aust* 1969 May 17;1(20):1016–9.
- [7] Gale GB, O'Connor DM, Chu JY. Normal values of α -fetoprotein in neonates and infants. *Paediatrics* 1988 July;82(1):138.
- [8] Gerber RE, Kamaya A, Miller SS, Madan A, Cronin DM, Dwyer B, et al. Fetus in fetu: 11 fetoid forms in a single fetus: review of the literature and imaging. *J Ultrasound Med* 2008 Nov;27(11):1562.
- [9] Gonzalez-Crussi F. Extragonadal teratomas. Armed forces institute of pathology (US); universities associated for research and education in pathology. Washington, D.C.: Published by the Armed Forces Institute of Pathology under the auspices of Universities Associated for Research and Education in Pathology; 1982.
- [10] Willis RA. The structure of teratomata. *J Pathol Bacteriol* 1935;40:1–36.
- [11] Bassetto MA, Franceschi T, Lenotti M, Parise G, Pancheri F, Sabbioni R, et al. AFP and HCG in germ cell tumors. *Int J Biol Markers* 1994;9(1):29–32.
- [12] Satgé D, Jaubert F, Sasco AJ, Vekemans MJ. Are fetus-in-fetu highly differentiated teratomas? Practical implications. *Pediatr Int* 2003 Jun;45(3):368.
- [13] Hoeffel CC, Nguyen KQ, Phan HT, Truong NH, Nguyen TS, Tran TT, et al. Fetus in fetu: a case report and literature review. *Pediatrics* 2000 June;105(6):1335–44.
- [14] Hopkins KL, Dickson PK, Ball TI, Ricketts RR, O'Shea PA, Abramowsky CR. Fetus-in-fetu with malignant recurrence. *J Pediatr Surg* 1997 Oct;32(10):1476–9.
- [15] Ji Y, Chen S, Zhong L, Jiang X, Jin S, Kong F, et al. Fetus in Fetu: two case reports and literature review. *BMC Pediatr* 2014 Apr 2;14:88.
- [16] Knox AJ, Webb AJ. The clinical features and treatment of fetus in fetu: two case reports and a review of the literature. *J Pediatr Surg* 1975 Aug;10(4):483–9.
- [17] Chen CP, Chern SR, Liu FF, Jan SW, Lee HC, Sheu JC, et al. Prenatal diagnosis, pathology, and genetic study of fetus in fetu. *Prenat Diagn* 1997 Jan;17(1):13–21.
- [18] Lewis RH. Foetus in foetu and the retroperitoneal teratoma. *Arch Dis Child* 1961 Apr;36:220–6. PubMed PMID: 13761753.